

The Sound That Failed

Michael S. Donnenberg, MD, Michael T. Collins, MD, R. Michael Benitez, MD,
Philip A. Mackowiak, MD

PRESENTATION OF CASE

The patient, a 56-year-old man, presented in early December with chills, fever, dyspnea, scant hemoptysis, and right-sided chest pain (1–3). He had been in his usual state of health until 2 weeks before presentation, when he noted loss of appetite, diarrhea, weight loss, increased thirst, and swelling of his feet and abdomen. At the time, he had been visiting his brother's country home where he had worked many hours in the cold, dressed in only flimsy clothing. His symptoms worsened markedly 2 days before presentation during a return trip to his own home in an open-air cart.

The patient had long had several disabilities, of which the most distressing was progressive hearing loss. The hearing difficulty and tinnitus began when the patient was in his mid-twenties. High-pitched tones were lost initially, and then low tones, first on the left and then the right. The patient used various ear trumpets to assist his hearing in the latter stages of his evolving deafness (Figure 1) (4). However, by the age of 44 years, his deafness was complete. He worked as both a musician and a composer. Although the deafness did not diminish his productivity as a composer, it gradually robbed him of his capacity to play and appreciate music. Recurrent bouts of depression ensued, along with increasing social isolation and personal neglect.

Beginning in his early twenties, the patient experienced recurrent bouts of abdominal pain accompanied by alternating diarrhea and constipation, the latter sometimes escalating to the level of obstipation (5). Initially, his pain was relieved by alcohol. However, in later years, alcohol appeared to worsen the abdominal pain and diarrhea. Although he complained of associated anorexia and ate irregularly and poorly, he maintained a robust appearance and highly energetic demeanor. He enjoyed a respite from these complaints during his forties, only to see them recur in his early fifties.

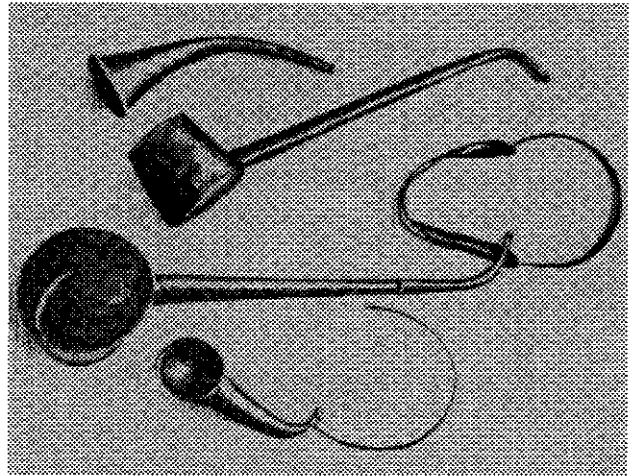


Figure 1. Various ear trumpets devised for the patient. Reprinted from (4) with permission.

The patient had smallpox as a child, as well as a febrile illness thought to have been either typhus or typhoid fever (1–3). He had intermittent winter attacks of “asthma” since the age of 17 years. In his late forties, he noted the onset of chronic headaches and recurrent joint pains, which were thought to represent either rheumatism or gout. At the age of 51 years, he experienced an episode of jaundice that lasted about 6 weeks before resolving. Three years before presentation, he developed a “painful eye affliction,” which apparently was treated with patching and which resolved 9 months after it appeared. At about this same time, he noted gradually increasing lower extremity edema accompanied by intermittent bouts of epistaxis, hematemesis, and hemoptysis.

The patient's alcoholic father died at age 52 years of unknown causes (1–3). His mother died at age 35 years of presumed tuberculosis. One brother and a sister died shortly after birth and another brother at age 2 years, all of unknown causes, although tuberculosis was suspected. Another brother died at age 41 years of suspected poisoning, and a fourth brother lived to age 72 years before dying of what was presumed to be atherosclerotic heart disease.

The patient was unmarried. Details of his sexual activities are unknown. He did not smoke. He consumed moderate to large quantities of alcohol daily, sometimes in the form of cheap, perhaps adulterated, wines (6). He also consumed a wide variety of unspecified medications

Am J Med. 2000;108:475–480.

From the Department of Medicine, University of Maryland School of Medicine and the Medical Care Clinical Center, Veterans Affairs Maryland Health Care System, Baltimore, Maryland.

Requests for reprints should be addressed to Philip A. Mackowiak, MD, Medical Service 111, Veterans Affairs Medical Center, 10 North Greene Street, Baltimore, Maryland 21201.

Manuscript submitted November 18, 1999, and accepted November 30, 1999.

in an arbitrary manner (5). These he apparently received ad libitum from his younger brother, who was a pharmacist.

Physical examination revealed a stocky, powerfully built but somewhat emaciated man of swarthy complexion (1-3). He appeared acutely ill. His face was flushed and prominently pockmarked. His lips were thin and parched, his tongue dry and coated. The hard palate was unusually rugose. The tonsils were small. There was scarring of the posterior pharyngeal wall. The skin was hot, flushed, and dry, and although densely hirsute, exhibited some evidence of hair loss. The chest was large and heaved noticeably as the patient struggled to breathe. The abdomen was distended and dull to percussion. Tenderness and splinting in the right upper quadrant prevented palpation of the liver. The tenderness extended into the right lower chest. Pitting edema was present in both lower extremities.

The patient was given a provisional diagnosis of pneumonia and treated with vigorous antipyretic therapy consisting of a series of herbal concoctions (1-3). A diaphoretic crisis ensued, and by the fifth day, the patient was feeling sufficiently improved to resume work on one of his compositions. However, on the seventh night of illness, he developed vomiting and diarrhea. By the next morning, he was intensely jaundiced and had marked tenderness in the right upper abdomen. He was again febrile. Repeat physical examination revealed an enlarged and nodular liver and increased edema of the legs and feet.

During the next week, the jaundice and edema increased and urinary output decreased. By the third week, his abdomen had become so distended with ascites that he was having respiratory difficulty. Paracentesis of 11 liters of fluid provided immediate relief. However, erysipelas developed at the puncture site and required several weeks of aggressive local therapy before resolving. Three additional paracenteses were performed during the ensuing weeks. These were complicated by chronic seepage from the puncture sites. To manage the seepage, the patient was nursed on a bed of straw, which became infested with vermin (5).

The patient became increasingly anorexic, emaciated, and constipated. Warholderthee and cabbage baths were given unsuccessfully in an attempt to induce diuresis (1). Iced alcoholic punch, one of the patient's favorite drinks, enabled him to sleep through an entire night for the first time in weeks. The next day he had a profuse diuresis and felt so much better he was able to resume work on one of his compositions. Encouraged by its apparent salutary effects, he began to consume large quantities of punch. Within a few hours, he developed abdominal pain and diarrhea, and then semicomatose with stertorous breathing. All alcohol was withheld until the patient recovered.

Thereafter, he was given only small doses of wine as a stimulant several times a day.

During the ensuing 3 months, his condition slowly deteriorated (1-3). The initial stimulant effect of the wine on his appetite waned. He became progressively cachectic and depressed. During this same period, he had increasingly frequent bouts of hemoptysis and epistaxis. In the final phase of his illness, he became anuric; he became comatose and then died. A postmortem examination was performed.

DIFFERENTIAL DIAGNOSIS

Dr. Michael S. Donnenberg: The principal signs and symptoms exhibited by this patient can be divided into those specific to his terminal illness and those of more long-standing duration. The tempo of his deterioration suggests an acute decompensation superimposed on a chronic disease, possibly associated with one or more troubling but nonfatal medical conditions. The fever and chills suggest an acute infection, which at first glance might have been pneumonia, given the dyspnea, chest pain, and hemoptysis. Cholangitis in the setting of biliary obstruction, or gram-negative sepsis from another source, are also considerations. However, it is also possible that the patient had pneumococcal peritonitis as a complication of pneumococcal pneumonia.

The patient's massive ascites was most likely a consequence of cirrhosis, as were his hemoptysis, hematemesis, and epistaxis, which suggest that he had liver failure complicated by a profound coagulopathy. The episodes of bleeding 2 years before his terminal illness suggest that hepatic dysfunction began long before the final hospitalization. The episode of jaundice 5 years before his death suggests that the liver failure was the result of a chronic disorder with acute exacerbations and remissions.

The patient's deafness might have been the result of either conductive or sensorineural hearing loss. Rinne and Weber tests would have been helpful in distinguishing these two possibilities. Unfortunately, the results of these tests were not given. The history of tinnitus and the early loss of high-frequency hearing strongly suggest sensorineural rather than conductive hearing loss. The psychosocial problems might simply have been a reaction to the progressive hearing loss and its devastating effect on his work as a musician and composer.

The 9-month episode of unilateral eye pain is intriguing. There was no mention of a discharge indicative of conjunctivitis. Therefore, I am inclined to attribute these symptoms to an attack of uveitis, treated with patching because of associated photophobia. Spontaneous remissions are common in many forms of uveitis.

Because hepatic failure was the dominant feature of the patient's terminal illness, it is appropriate to begin the

differential diagnosis with a discussion of possible causes of his hepatic abnormalities. The palpable hepatic nodules might have been the result of either cancer or macronodular cirrhosis. Liver metastases rarely cause hepatic failure. However, hepatoma, which frequently arises in the setting of cirrhosis, is commonly accompanied by hepatic failure. The hepatic nodules might have been the result of multifocal hepatoma but were more likely the result of macronodular cirrhosis. Alcoholic cirrhosis, although classically micronodular, occasionally presents with large hepatic nodules. The patient's penchant for alcoholic beverages raises the possibility of such a variant of Laennec's cirrhosis. However, postnecrotic cirrhosis is a more likely explanation.

Most cases of postnecrotic cirrhosis represent the terminal phase of chronic active hepatitis caused by hepatitis B or hepatitis C viruses. Although it is conceivable that the transient episode of jaundice 4 years before the patient's terminal illness represented his initial infection with one of these viruses, chronic active hepatitis usually takes considerably longer to progress to cirrhosis.

Hemochromatosis is a cause of cirrhosis that, in some respects, is more consistent with the patient's clinical course. Its hallmark is widespread iron deposition that causes fibrosis and dysfunction of multiple organ systems, especially the liver, pancreas, heart, and skin. Alcohol potentiates the adverse effects of hemochromatosis on the liver, accelerating the evolution of cirrhosis. Abdominal pain, which is sometimes severe, depression, arthralgias, and arthritis are common. Overt diabetes mellitus develops in approximately 40% of patients, and congestive heart failure in about 30%. The patient's "swarthy complexion" might, perhaps, have represented cutaneous hyperpigmentation, another common feature of hemochromatosis.

The patient had many chronic gastrointestinal complaints that might be explained in a variety of ways, one of which is that he had inflammatory bowel disease. The symptoms of inflammatory bowel disease usually begin between the ages of 15 and 30 years. Patients with ulcerative colitis often have constipation, tenesmus, and hematochezia. Mucous, blood, and pus are commonly found in the stool. Although patients may complain of abdominal cramping, abdominal pain is not usually a prominent symptom. Both pain and diarrhea are prominent symptoms of regional enteritis. Abdominal pain frequently indicates the presence of obstruction resulting from edema, spasm, or fibrosis. Fistula formation is a hallmark of the disorder, but was not mentioned in the patient's history.

Uveitis is an occasional extraintestinal manifestation of inflammatory bowel disease. Moreover, 3% of patients with ulcerative colitis have associated sclerosing cholangitis, which can progress to biliary cirrhosis with ascites. As such, ulcerative colitis might explain several features

of our patient's illness. However, biliary cirrhosis would be an unlikely cause of his macronodular cirrhosis, because of the lack of a history of sustained jaundice and pruritus.

Whipple's disease, a multisystem disorder caused by *Tropheryma whippeli*, is yet another condition that might explain some of the patient's complaints. Weight loss, arthritis, and diarrhea are its most common symptoms. Central nervous system dysfunction and hyperpigmentation are occasional features, as are abdominal pain and uveitis. However, ascites is rare, and when present, it is the consequence of hypoalbuminemia and lymphatic obstruction rather than cirrhosis.

Irritable bowel syndrome, I believe, is the most likely explanation for the patient's intestinal complaints. A common disorder, it generally begins during adolescence or early adulthood. Patients with irritable bowel syndrome characteristically complain, as did this patient, of alternating constipation and diarrhea. They do not report the presence of blood, pus, or fat in their stools. Psychiatric disturbances, most notably depression and anxiety, have been reported in 70% to 80% of patients.

In view of the chronicity of our patient's complaints and the evidence of dysfunction of multiple organ systems, systemic lupus erythematosus must be added to the list of possible diagnoses. Lupus could certainly explain the patient's joint complaints, and might also explain his pleuritic chest pain and erratic behavior. However, chronic diarrhea and hearing loss are not typical of lupus, and although lupus is sometimes associated with hepatitis, liver failure rarely results. Uveitis is also rare in lupus. The episode of uveitis and the chronic intestinal complaints also raise the possibility of reactive arthritis. However, reactive arthritis would not explain his liver failure or deafness.

Of the granulomatous diseases that might have caused the patient's multisystem disorder, sarcoidosis should be considered. It is a disorder of unknown etiology, usually presenting between 20 and 40 years of age. Although the thorax is the site most often involved by sarcoid granulomas, any organ may be affected. Uveitis and arthritis are common complications. Central nervous system involvement occurs in approximately 5% of patients and is characterized by granulomatous infiltration of the meninges and cranial nerves. Both fluctuating hearing loss resulting from reversible neuropathy and deafness resulting from vasculitis have been reported. However, destruction of the auditory nerve by sarcoidosis is extremely rare. Moreover, although granulomatous infiltration of the liver is common, such infiltration is focal and does not progress to cirrhosis. Involvement of the intestine by sarcoidosis rarely occurs.

Of all the diseases that might explain the patient's many complaints, none is more plausible than syphilis. Syphilis is a multisystem disorder, capable of causing pro-

gressive multiorgan dysfunction over many decades. Ten to 15% of patients with untreated syphilis develop ocular abnormalities. By far the most common of these is uveitis, principally iridocyclitis, which typically manifests during the secondary phase of the infection. The iridocyclitis is associated with severe ocular pain and photophobia. Neurosyphilis, manifested principally as chronic meningitis, develops in 5% to 8% of untreated patients. It is doubtful that the patient had parenchymal neurosyphilis, because his intellect seems to have been spared. However, cranial nerves are commonly involved in chronic meningitic syphilis, especially the eighth nerve. In fact, positive serologic tests for syphilis have been reported in 7% of patients with unexplained sensorineural hearing loss (7). Syphilitic otitis also causes tinnitus and either sudden or insidious hearing loss, which may progress to total deafness. Syphilitic otitis is often bilateral (7).

In earlier times, granulomas and gummas of the liver were common in patients with untreated tertiary syphilis. The third edition of Cecil's textbook of medicine lists syphilis just below alcohol and "highly seasoned foods" as the third most important cause of cirrhosis. Autopsy series from that era identified evidence of hepatic syphilis in nearly one-third of patients with cirrhosis, 18% of whom had palpable nodules and 3% of whom had ascites (8,9). Thus, untreated syphilis is a reasonable explanation for the patient's deafness, ocular complaints, inappropriate behavior, macronodular cirrhosis, and ascites. It is not, however, a likely explanation for his chronic intestinal complaints, in that symptomatic syphilis enteritis is rare, even in advanced cases of the infection.

Ultimately, I am unable to attribute all of the patient's signs and symptoms to a single diagnosis. Because his disabilities evolved over 56 years, it is conceivable, and perhaps likely, that he was afflicted by more than one disease at the time of his death. Of those worthy of consideration, I believe that syphilis offers the best explanation for most of his disabilities, including his episode of eye pain, hepatic failure, deafness, joint complaints, and perhaps even his erratic behavior. I believe that his final illness was spontaneous bacterial peritonitis, with hepatic decompensation. His long-standing gastrointestinal complaints, I believe, are best explained by irritable bowel syndrome.

Dr. Michael S. Donnenberg's diagnoses: pneumonia, possibly complicated by bacterial peritonitis; tertiary syphilis with gummatous cirrhosis, luetic otitis, and luetic iridocyclitis (resolved); irritable bowel syndrome.

AUTOPSY FINDINGS

The subject of this clinicopathologic exercise is Ludwig van Beethoven (Figure 2), who died on March 27, 1827. A postmortem examination was performed and recorded by Dr. Johann Wagner, then an assistant at the Vienna




Figure 2. Beethoven at age 48 years, when he was nearing total deafness, as depicted in a pencil drawing by August von Klöber, 1818. Reprinted from (28) with permission.

Pathologic Museum. His findings, originally written in Latin, were lost and then rediscovered in 1970. Wagner's autopsy report was as follows (3):

"The corpse was very emaciated, especially in the limbs, and sown over with black Petechien; the abdomen, which was unusually dropsied, was distended and stretched.

The external ear was large and irregularly formed, the scaphold fossa but more especially the concha was very spacious and half as large again as usual; the various angles and sinuosities were strongly marked. The external auditory canal was covered with shining scales, particularly in the vicinity of the tympanum, which was concealed by them. The Eustachian tube was much thickened, its mucous lining swollen and somewhat contracted about the osseous portion of the tube. In front of its orifice and toward the tonsils some dimpled scars were observable. The principal cells of the Mastoid process, which was large and not marked by any notch, were lined with a vascular mucous membrane. The whole substance of the Os petrosum showed a similar degree of vascularity, being traversed by vessels of considerable size, more particularly in the region of the cochlea, the membranous part of its spiral lamina appearing slightly reddened.

The facial nerves were of unusual thickness, the auditory nerves, on the contrary, were shriveled and destitute

Table. Beethoven's Diseases

Organ System	Symptoms	Pathologic Findings	Suggested Diagnoses (reference)
Neurologic	Progressive hearing loss and tinnitus, chronic headaches, depression, social isolation, and personal neglect	Scaly external auditory canal; thickened Eustachian tube; shriveled auditory nerves with associated dilated and "cartilaginous" arteries; cerebral convolutions full of water, remarkably white, and deeper, wider, and more numerous than ordinary	Syphilis (4,10,11), otosclerosis (4,12), sarcoidosis (13,14), Paget's disease (15), typhus (16), measles (4), scarlatina (4), Whipple's disease (17), systemic lupus erythematosus (18)
Gastrointestinal	Chronic, intermittent, abdominal pain; diarrhea and constipation; jaundice, ascites, edema, and coagulopathy	Stomach and bowels greatly distended with air; macronodular cirrhosis; greyish-brown, turbid, ascitic fluid; splenomegaly; hard pancreas with a dilated duct	Irritable bowel syndrome (12,19-21), inflammatory bowel disease (12,19-21), auto-intoxication (16,22), Whipple's disease (17), sarcoidosis (13,14), typhus (15), syphilis (4,10,11), hemochromatosis (6), Laennec's cirrhosis (1,23,24), viral hepatitis (22,25), primary sclerosing cholangitis (26), alcoholic pancreatitis (27), diabetes mellitus (27)
Renal	Terminal anuria; recurrent abdominal pain	Thickened Gerota's capsule, calcareous caliceal concretions	Analgesic nephropathy (27), papillary necrosis (27), Whipple's disease (17), sarcoidosis (13,14), Paget's disease (15), inflammatory bowel disease (12,19-21)
Pulmonary	"Asthma"; terminal fever, dyspnea, and hemoptysis	Chest cavity and organs "in normal condition"	Syphilis (4,10,11), systemic lupus erythematosus (18), Whipple's disease (17), sarcoidosis (13,14), inflammatory bowel disease (12,19-21)
Ocular	Painful eye attack	Not stated	Syphilis (4,10,11), Whipple's disease (17), systemic lupus erythematosus (18), sarcoidosis (13,14), Paget's disease (15), inflammatory bowel disease (12,19-21)
Articular	Recurrent attacks of "gout/rheumatism"	Not stated	Syphilis (4,10,11), Whipple's disease (22), systemic lupus erythematosus (18), sarcoidosis (13,14), Paget's disease (15), inflammatory bowel disease (12,19-21)

of neurina; the accompanying arteries were dilated to more than the size of a crow quill and cartilaginous. The left auditory nerve much the thinnest, arose by three very thin grayish striae, the right by one strong clearer white stria from the substance of the fourth ventricle, which was at this point much more consistent and vascular than in other parts. The convolutions of the brain were full of water, and remarkably white; they appeared very much deeper, wider, and more numerous than ordinary.

The Calvarium exhibited throughout great density and a thickness amounting to about half an inch.

The cavity of the Chest, together with the organs within it, was in the normal condition.

In the cavity of the Abdomen four quarts of a grayish-brown turbid fluid were effused.

The liver appeared shrunk up to half its proper volume, of a leathery consistence and greenish-blue color, and was beset with knots, the size of a bean, on its tuber-

culated surface, as well as in its substance; all its vessels were very much narrowed, and bloodless.

The Spleen was found to be more than double its proper size, dark-colored and firm.

The Pancreas was equally hard and firm, its excretory duct being as wide as a goosequill.

The Stomach, together with the Bowels, was greatly distended with air. Both Kidneys were invested by cellular membrane of an inch thick, and infiltrated with a brown turbid fluid; their tissue was pale-red and opened out. Every one of their calices was occupied by a calcareous concretion of a wart-like shape and as large as a split pea. The body was much emaciated."

COMMENT

Dr. R. Michael Benitez and Dr. Philip A. Mackowiak: Volumes have been written about Beethoven's illnesses and

death. For his own part, Beethoven left a rich record of his symptoms in the form of his "conversation books" and extensive correspondences with his physicians, relatives, and friends (1-3). The rediscovery in 1970 of his original autopsy report stimulated additional interest in his medical condition. The purpose of the current exercise has been to explore, yet again, Beethoven's medical history in the light of modern medical knowledge using the clinicopathologic conference format.

Previous attempts to identify the cause of Beethoven's illnesses have produced an argosy of diagnoses (Table), the diversity of which reflects the array of the signs and symptoms that occurred during his 56 years of suffering. No diagnosis has been universally accepted as the etiology of any of Beethoven's complaints, although there is a consensus that no one disease can have caused all of his complaints. The theory that syphilis is the best explanation for most of his complaints is not new (6,10,11). McCabe (6) eloquently advanced this hypothesis in an article published in 1958. In it, he referred to comments by Reis, a close friend of Beethoven, that contrary to the legend that Beethoven "had always been above the more obvious frailties of the flesh," "he was practically never out of [love]." McCabe suggested that this and similar statements by Beethoven's associates established the existence of opportunities by which Beethoven might have been exposed to *Treponema pallidum*. McCabe, like Dr. Donnenberg, also pointed to the many features of Beethoven's illness that are best explained by advanced syphilis. Finally, he argued that the central nervous system findings at postmortem examination were most consistent with a chronic basilar piarachnoiditis and eighth-nerve arteritis, again, best explained by syphilis.

Of the many lingering mysteries concerning Beethoven's illness, none is more intriguing than its possible effect on his creativity and productivity. During his 56 years, Beethoven produced nine symphonies, five piano concertos, one violin concerto, 17 string quartets, one opera, and 32 piano sonatas (12). At the time of his death he was hard at work on two other major pieces that were left unfinished, his *Missa Solemnis* and the oratorio, *Saul and David* (1). Whether disease, in particular Beethoven's deafness, was detrimental or, to the contrary, enabled Beethoven to "hear" the polyphonic music of his third (deaf) period, which was perhaps his greatest legacy as a composer, is more problematic. This question, like the one concerning the etiology of his many illnesses, will no doubt continue to intrigue medical investigators for as long as physicians maintain an interest in music and the arts.

ACKNOWLEDGMENT

This case discussion was originally presented as one of a series of historical clinicopathologic conferences sponsored by the Veterans Affairs Maryland Health Care System and the University

of Maryland School of Medicine. We are indebted to Bayer Pharmaceuticals for an unrestricted continuing educational grant that helped bring the conference to fruition.

REFERENCES

1. London SJ. Beethoven: case report of a titan's last crisis. *Arch Intern Med.* 1964;113:442-448.
2. Neumayr A. *Music and Medicine. Haydn, Mozart, Beethoven, Schubert. Notes on Their Lives, Works, and Medical Histories.* Translated by B.C. Clarke. Bloomington: Medi-Ed Press, 1994:225-236.
3. Forbes E, ed. *Thayer's Life of Beethoven.* Princeton, NJ: Princeton University Press, 1973.
4. McCabe BF. Beethoven's deafness. *Ann Otol Rinol Laryngol.* 1958; 67:192-206.
5. Schwarz A. Beethoven's renal disease based on his autopsy: a case of papillary necrosis. *Am J Kid Dis.* 1993;21:643-652.
6. Davies PJ. Was Beethoven's cirrhosis due to hemochromatosis? *Renal Failure.* 1995;17:77-86.
7. Rothenberg R. Syphilitic hearing loss. *South Med J.* 1979;72:118-119.
8. Schumacher GA. Causative factors in the production of Laennec's cirrhosis with special reference to syphilis. *Am J Med Sci.* 1937;194: 693-700.
9. Stokes JH, Beerman H, Ingraham NR Jr. *Modern Clinical Syphilology. Diagnosis. Treatment. Case Study.* Philadelphia: WB Saunders, 1944:852.
10. von Frimmel T. *Beethoven-Handbuch 1:38.* Leipzig: Druck and Verlag con Breitkopf & Härtel, 1926.
11. Jacobsohn L. Beethovens Geliorleiden und letzte Krankheit. *Deutsche Med Wochenschr.* 1927;53:1610.
12. Kubba AK, Young M. Ludwig van Beethoven: a medical biography. *Lancet.* 1996;347:167-170.
13. Palferman TG. Classical notes: Beethoven's medical history, a variation on a rheumatological theme. *J R Soc Med.* 1990;83:640-645.
14. Drake ME Jr. Deafness, dysesthesia, depression, diarrhea, dropsy, and death: the case for sarcoidosis in Ludwig van Beethoven. *Neurology.* 1994;44:562-565.
15. Naiken VS. Did Beethoven have Paget's disease of bone? *Ann Intern Med.* 1971;74:995-999.
16. Schweisheimer W. *Beethovens Leiden: ihr Einfluss auf sein Leben und Schaffen.* Munich: Georg Muller, 1922.
17. Forster W. *Beethovens Krankheiten und ihre Beurteilung.* Wiesbaden: Breitkopf und Hiirtel, 1956.
18. Larkin E. Beethoven's medical history. In: Cooper M, ed. *Beethoven: The Last Decade.* Oxford: Oxford University Press, 1970:448-449.
19. Neumayr A. *Musik, and Medizin.* Vienna: Edition Wien, 1987:185-187.
20. Klotz-Forest. La dernière maladie et al mort de Beethoven. *La Chronique Médicale.* 1906;13:241-249.
21. Critchley M, Henson RA, eds. *Music and the Brain.* London: William Heinemann, 1977:402.
22. Sharma O. Beethoven's illness: Whipples disease rather than sarcoidosis? *J R Soc Med.* 1994;87:283-285.
23. Franken FH. *Die Krankheiten grosser Komponisten, vol 1.* Wilhelmshaven: Florian Noetzel Verlag, 1986:101-108.
24. O'Shea J. *Music, and Medicine. Medical Profiles of Great Composers.* London: JM Dent, 1990:39-65.
25. Piroth M. Beethovens letzte Krankheit auf Grund der zeitgencissichen medizinischen Quellen. *Beethoven Jahrbuch.* 1959;60:7-35.
26. Adams PC. Historical hepatology: Ludwig van Beethoven. *J Gastroent Hepatol.* 1987;2:375-379.
27. Davies PJ. Beethoven's nephropathy and death. *J Roy Soc Med.* 1993;86:159-161.
28. Schwarz A. Beethoven's renal disease based on his autopsy: a case of papillary necrosis. *Am J Kid Dis.* 1993;21:643-652.